

Neurofibromatosis

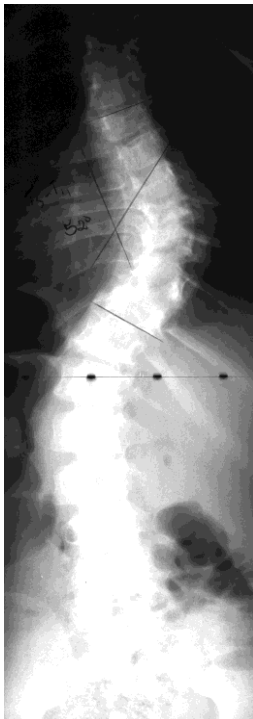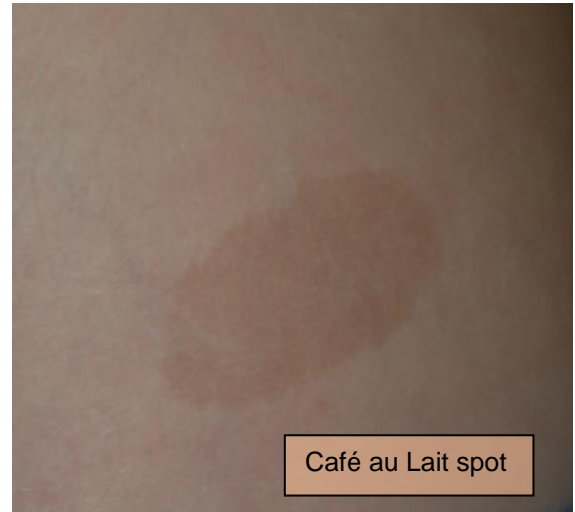Definition:

Neurofibromatosis is a disturbance in the development of the supportive tissues of the nervous system. It involves many different body systems, is present at birth and sometimes runs in families.

Neurofibromatosis occurs in 1 of 2,500 to 3,000 persons. It is passed on from parent to child as an autosomal dominant trait.

Diagnostic Criteria:

1. Six or more birth marks called "café au lait spots" which are greater than 5mm. Café au lait spots are usually light brown in color, like coffee with cream.
2. Two or more neurofibromas of any type or one plexiform neurofibroma.
3. Freckling in the underarm or groin regions.
4. Optical glioma.
5. Two or more Lisch nodules (iris hamartomas).
6. A bone lesion characteristic of neurofibromatosis.
7. A first degree relative (parent, sibling, or offspring) with neurofibromatosis identified with the above criteria.



Characteristics:

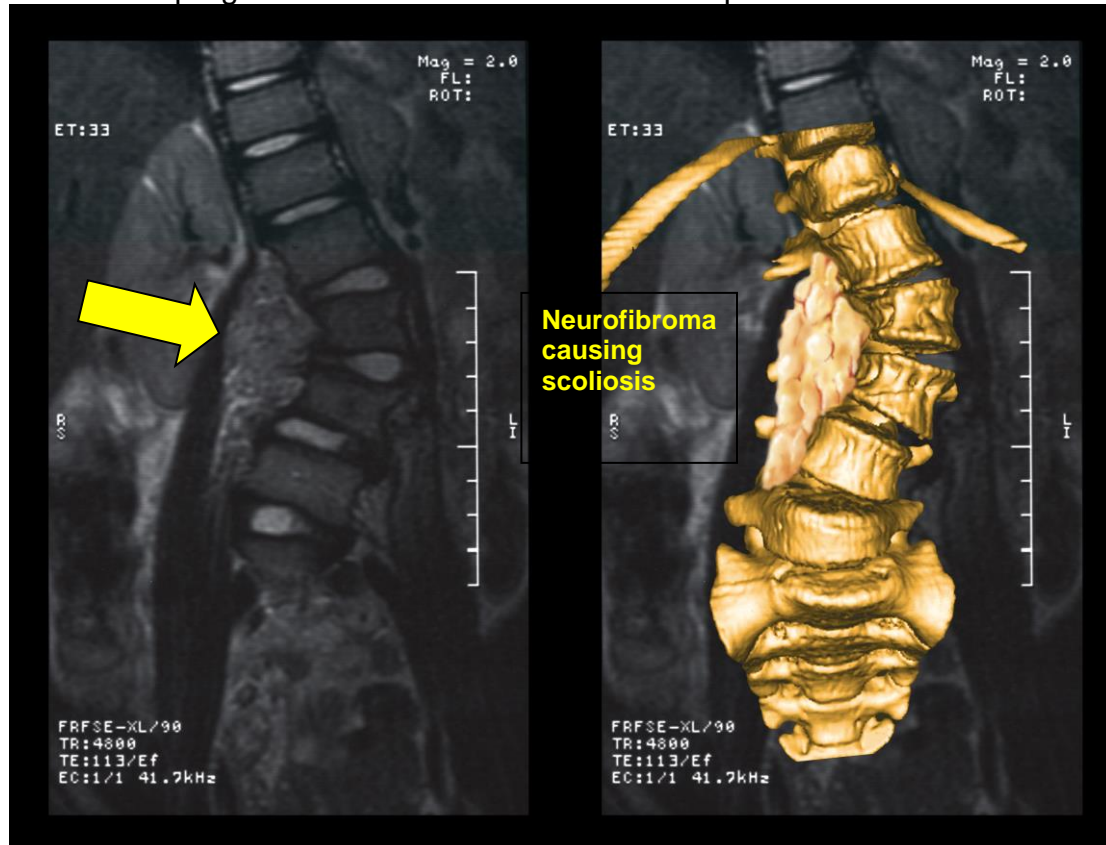
The most common musculoskeletal manifestations are:

- spinal deformity,
- limb-length discrepancy,
- pseudarthrosis of the tibia,
- pathologic fractures
- hemihypertrophy of the foot, face, and hand.

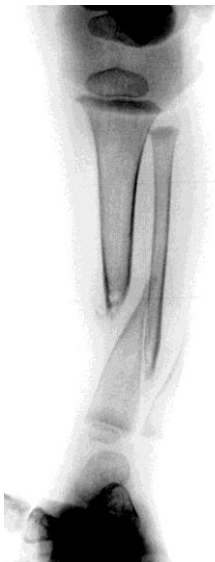Neurologic, visual, and hearing problems are characteristics of neurofibromatosis. Other manifestations of neurofibromatosis may include sexual precocity, learning disorders, extremely high blood pressure and mental retardation.

BONE ABNORMALITIES:

Deformity of the spine- Scoliosis is the most common bone problem and may be one of two types. Dysplastic spinal deformity tends to be progressive and to resist stabilization of the spine with bracing. Non-dysplastic spinal deformity shows less progression of the curve and better response to brace treatment.



Bone Overgrowth- Disorders of bone growth are fairly common manifestations of neurofibromatosis. The overgrowth in bone and soft tissues are usually on one side of the body. This may cause hemi-hypertrophy (one side is larger than the other) or limb length inequality.



Pseudarthrosis of tibia- This is characterized by an absence of normal bone in part of the shin bone. In place of the bone is a gristle-like substance that cause the bone to be weak, bowed, prone to fracture and resistant to healing. Type I have the best prognosis and may never progress to fracture. Management with bracing is usually unnecessary, unless the bowing starts to increase severely. Type II bowing may lead to fracture, and protective bracing is essential from the time of diagnosis. Type III is extremely susceptible to fractures. Type IV bowing has the worst prognosis and may require amputation.

PREVENTIVE TREATMENT: Genetic counseling is the only primary prevention. Secondary prevention refers to the early detection and removal of skin lesions that could be cancerous. Surgical excision of skin tumors is recommended if sudden rapid growth occurs. If the tumor is found to be malignant then further surgery will be necessary. Tumors involving the brain and spinal cord should be fully investigated and removed if feasible.

PROGNOSIS: It is impossible to predict the course of neurofibromatosis in anyone. A small number will have correctable problems. A few may have serious and persistent problems but most children with NF have mild forms of the disorder and lead healthy and productive lives.



©John T. Killian, M.D. & Sharon Mayberry, M.D.